

CLINICAL CASE REPORT

# Bone fenestration: A case report of management of a lower anterior buccal bone fenestration

Dr. Murai Khalifa<sup>1</sup>  
Yuliya Mulyar<sup>2</sup>


<sup>1</sup>BDS, DDS, GPR, McGill University, Family Dental Clinic, Strathmore, Alberta, Canada

<sup>2</sup>BA Psychology, DDS candidate Schulich School of Medicine & Dentistry, Western University, London, Ontario, Canada.

**Corresponding Author:**

Dr. Murai Khalifa  
Email: Murai.khalifa@mail.mcgill.ca

Access this Article Online

	www.idjsr.com
	Use the QR Code scanner to access this article online in our database
	Article Code: IDJSR 0162

Quick Response Code

### Abstract

The term fenestration refers to a circumscribed defect that creates a "window" through the bone over the prominent root. This lesion will be seen when the alveolar bone is exposed by a flap surgery, its associated with localized periodontal destruction. This case reports a 62year-oldmale patient who presented with persistent tooth pain at the lower right 2ed incisor, despite repeated root canal treatments by a general practitioner. When the patient visited our clinic, a CT examination was performed and apical fenestration was diagnosed. The tooth was not restorable due to a fracture in the apical third from a previous root canal therapy. Suggested treatment plan was to extract the tooth, perform bone grafting and a future implant.

**Keywords:** Bone fenestration; Tooth; Graft.

### Introduction

In a healthy periodontium the facial margin of the alveolar crest lies approximately 2 mm apical to the gingival margin, which courses near to the cement enamel junction. The facial aspect of the alveolar bone covering the root is usually very thin. As

revealed by a flap operation or on a skull preparation the coronal portion of the root is often not covered by bone "dehiscence" or there is a fenestration. Isolated areas in which the root is denuded of bone and the root surface is covered only by periosteum and overlying gingiva are termed *fenestrations*. In these areas, the marginal bone is intact [1,2]. Such defects occur on approximately 20% of the teeth; they occur more often on the facial bone than on the lingual bone, they are more common on anterior teeth than on posterior teeth, and they are frequently bilateral. Microscopic evidence of lacunar resorption may be present at the margins. The causes of these defects are not clear. However, predisposing factors include prominent root contours, malposition and labial protrusion of the root in combination with a thin bony plate[3].

### Incidence

The incidence of apical fenestration is between 7.5% and 20%, and is higher in the maxillary than in the mandibular teeth. It has also been reported that the incidences higher in the anterior than in the posterior teeth. The most commonly observed regions are the canine root and the mesio-buccal root of the maxillary first molar. Although the cause of apical fenestration is still unclear, it has been suggested that anatomical factors such as age-related changes and the positional relationship between the tooth and the alveolar bone might be involved. Moreover, occlusal dysfunction should also be considered.[4]

### Management

Fenestration and dehiscence defects have been managed with barrier membranes or simply with flap closure. Also, bone grafts has been used in this case. The only controlled comparison studies between membrane treatment and periosteal flap coverage of exposed implant surfaces in humans demonstrated that the membrane treatment was far superior with regard to bone fill.11Another controlled study in humans has shown better results in the membrane groups; Infour outof six sites (67%) treated with a membrane resulted in 95% to 100% elimination of the dehiscence and total coverage of the threads. In the control sites, only 2 of 6 sites (33%) showed moderate-to-complete bone fill.43All other clinical studies which are in the form of case reports,

demonstrates coverage of an implant dehiscence using a barrier membrane. Admittedly, without a biopsy, it cannot be determined whether the tissue covering the implant is bone or firm connective tissue.[5,6]

A one-year multicenter study evaluating 55 Brånemark implants (i.e., machined-surface, external hex) with bone dehiscence in 45 patients, treated by ePTFE membrane alone, demonstrated an average bone fill of 82%.12. The average initial defect height was 4.7 mm. The 1-year follow-up of these implants demonstrated a favorable response to loading. Of the 55 implants, a total of 6 failed, corresponding to a cumulative survival rate of 84.7% in the maxilla and 95.0% in the mandible, which is similar to previously published results for this implant design. A clinical report on the use of TR membranes demonstrated the biologic potential to fill a large protected space in four patients. 24Bone dehiscence at implant sites ranged from 5 to 12 mm (mean:8.2 mm). They were covered with a TR membrane alone (no graft).

Re-entry after 7 to 8 months of submerged healing found complete bone coverage over all the implants. Radiographic evaluation demonstrated that the implants were functioning with normal crestal bone support after 1 year.

No clinical comparisons are available in the literature evaluating the placement of bone grafts with or without barrier membranes on implant dehiscence defects. Most evidence supports the use of graft materials in conjunction with membrane treatment, particularly the use of FDBA in conjunction with GBR. In a study with 40 patients, 110 implants were placed in conjunction with barrier membranes and FDBA; a success rate of 96.8% was achieved with complete bone fill (defined as >90% fill of dehiscence)[7].This study reported a membrane exposure rate of 29%, but noted little adverse effect on the bone regeneration.

### Case report

A 62 years male patient presented to our clinic with persistent pain related to the lower 2ed right incisor tooth. Patient wanted the tooth extracted and implant placed. Patient medical history was normal. Upon oral examination, tooth 4.2 was positive to percussion with possible horizontal fracture. Mobility class II was noticed and upon radiographic examination, well circumscribed radiolucent lesion surrounding the apex of tooth 4.2 was notices, which turned to be a periapical granuloma after a biopsy.Fig 1,2

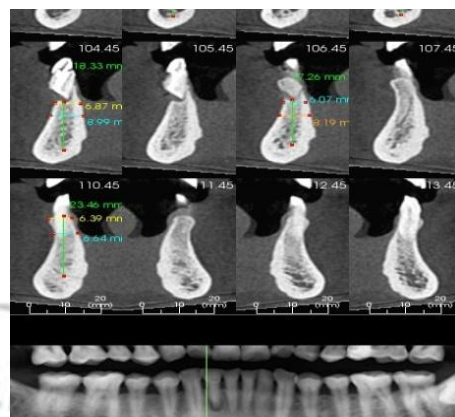


Figure 1. Preoperative diagnostic CT scan

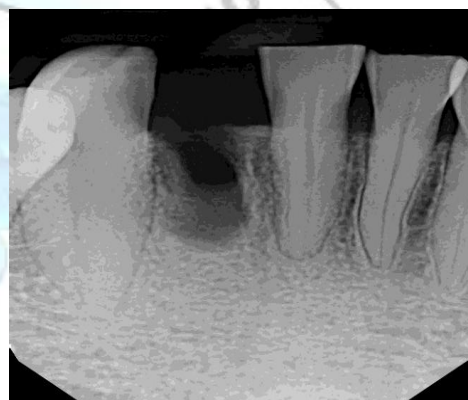

Figure 2. Post extraction Periapical radiograph

It was decided and explained to the patient that the best approach was to extract tooth 4.2 followed by a bone graft and an implant 6 months later. The patient consented to the proposed treatment and subsequently full mouth impressions were taken to develop study casts. Upon extraction, the bone fenestration was noticed with loss of the buccal alveolar bone wall. Fig3

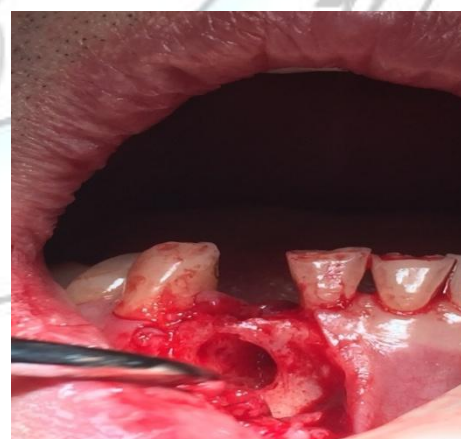
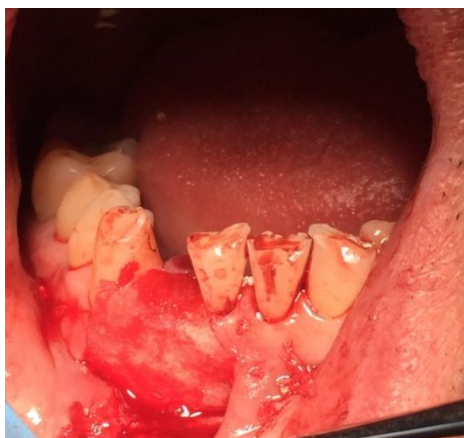
Figure 3. Intraoral view showing the alveolar bone loss and fenestration

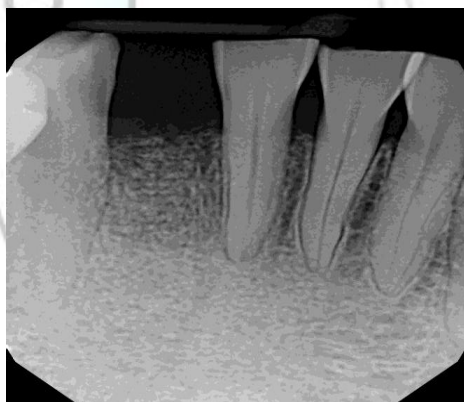
Curettage of the lesion was completed and was sent for biopsy. Next step was to graft the socket using 2

types of bone. We used a mix of allograft material which is composed of 50% mineralized cortical and 50% mineralized cancellous size 0.25 mm with the 4bone bch composed of 60 % hydroxyapatite and 40% beta-Tricalcium Phosphate that was covered with a resorbable membrane. Fig4



**Figure 4: Facial view showing bone graft covered by the membrane**

The flap then was closed using silk sutures size 3.0. An antibiotic course was started and analgesics were prescribed to patient and he was scheduled for follow-ups. Fig5



**Figure 5: Periapical radiograph 6 weeks follow up.**

The patient reported that pain and discomfort disappeared. Site healing was optimal and patient will be ready for an implant in a four months period.

## Conclusion

The etiology of bone fenestration is still unclear. In most cases, early diagnosis and treatment can lead to successful management and do not require extensive treatment. In this case, we were able to preserve the socket for a future implant and give patient more options to restore the missing tooth.

## References

1. Color atlas of Dental Medicine Periodontology By Herbert F. Wolf, Edith M. Rateitschak-Pluss
2. Caranza's Clinical periodontology , By Michael G. Newman, Henry Takei, Perry R. Klokkevold, Fermin A. Carranza
3. Elliot JR, Bowers GM: Alveolar dehiscence and fenestration. *Periodontics*1:245, 1963.
4. Bulletin of Tokyo Dental College, 53(1): 23-26
5. Jensen OT, Greer RO, Jr, Johnson L, et al: Vertical guided bone-graft augmentation in a new canine mandibular model. *Int J Oral MaxillofacImplants* 10:335-344, 1995.
6. Klokkevold PR, Han TJ, Camargo PM: Aesthetic management of extractions for implant site development: delayed versus staged implant placement. *Pract Periodontics Aesthet Dent* 11:603-610, quiz 612, 1999.
7. Klokkevold PR, Han TJ, Camargo PM: Aesthetic management of extractions for implant site development: delayed versus staged implant placement. *Pract Periodontics Aesthet Dent* 11:603-610, quiz 612, 1999.